The operating room of the future

Per Kristian Hol, MD, PhD

Oslo University Hospital

The Intervention Centre

The future: Image guided treatment

- **Super vision**
- **Super sensing**
- **Integrated knowledge**

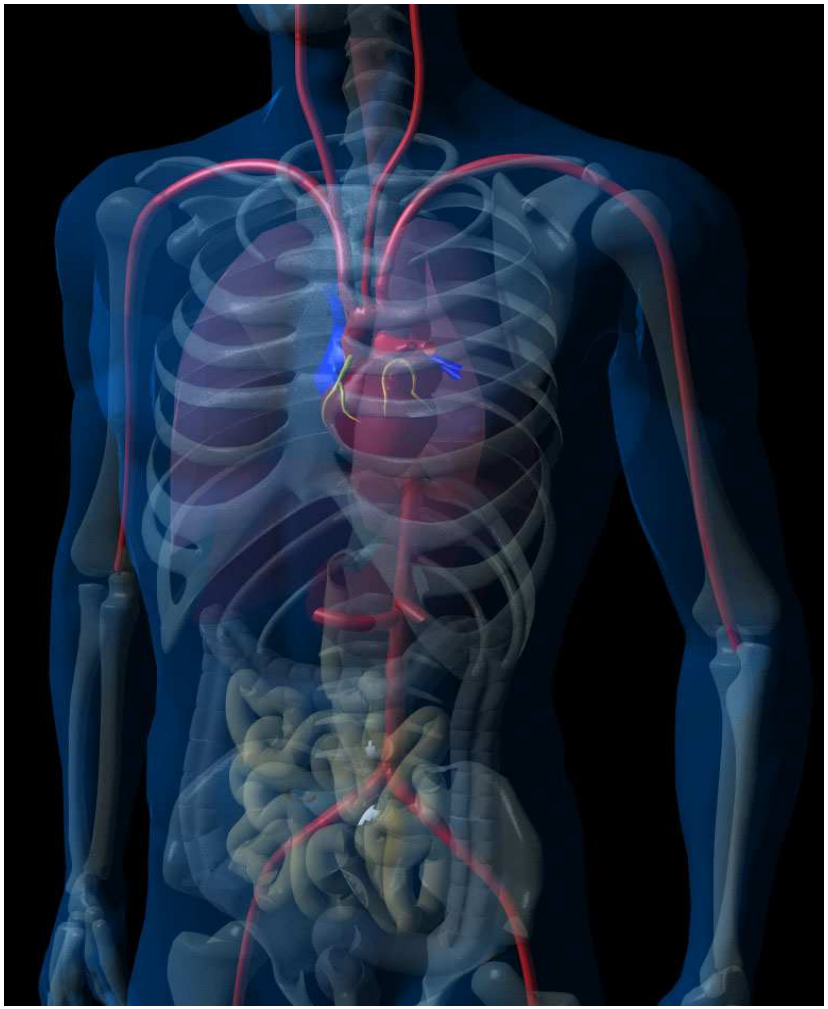

Navigation systems – Tracking devices

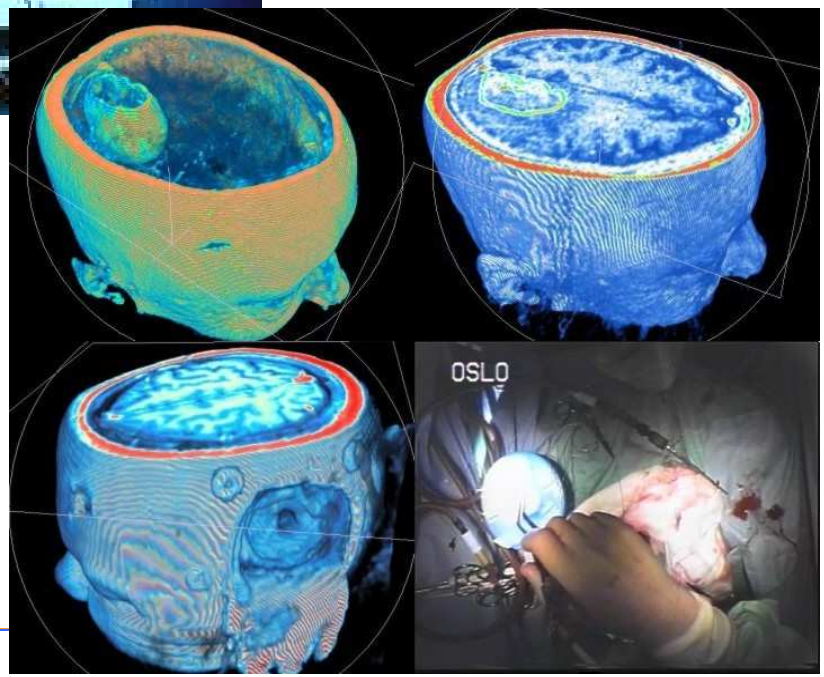

Oslo University Hospital

Segmentation - Image fusion

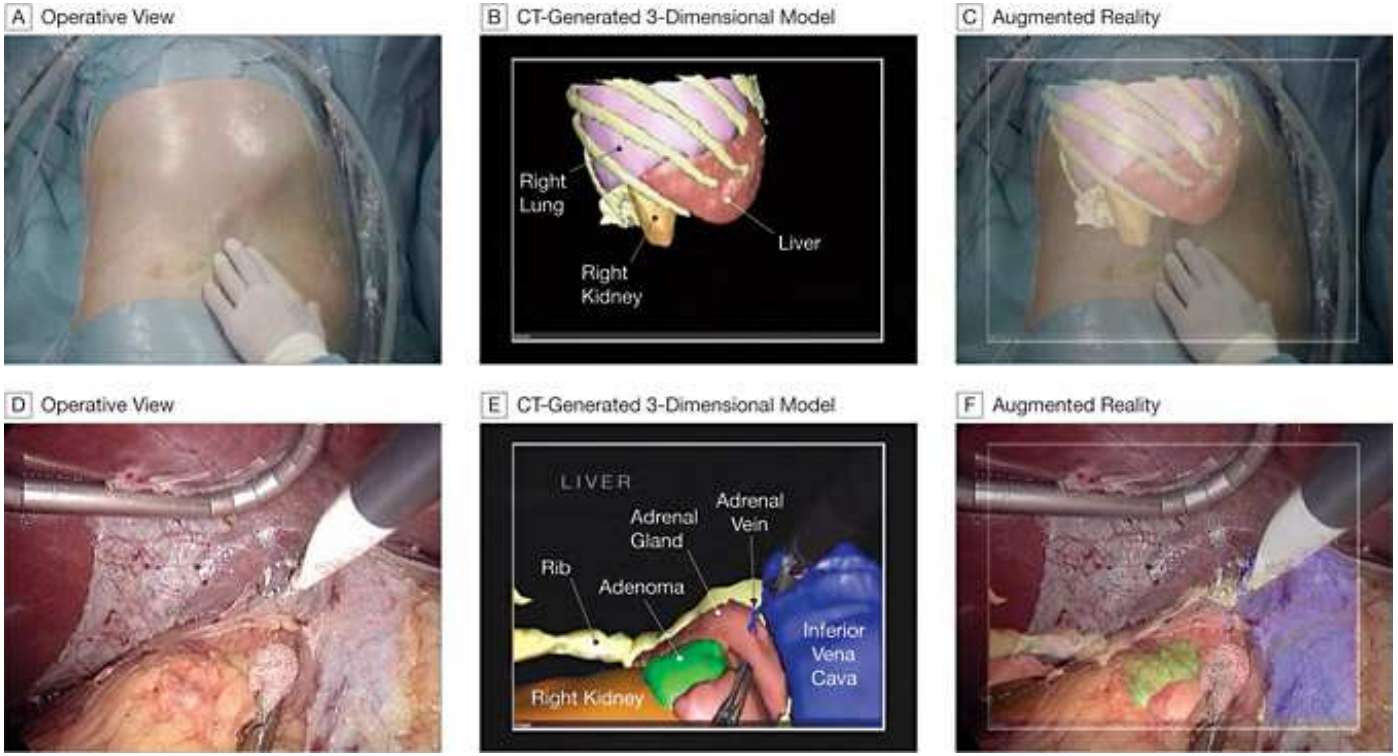

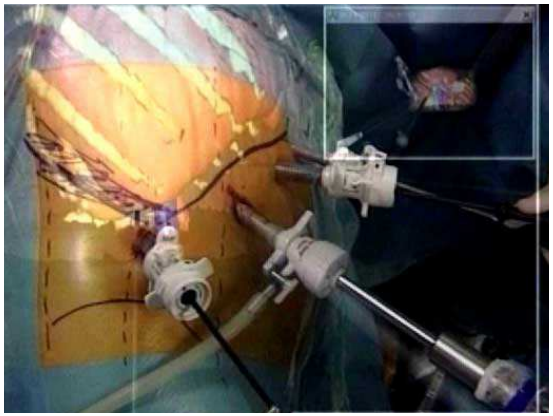

Marescaux, J. et al. JAMA 2004;292::2214

Ultrasound in operating room

Laparoscopic liver resection

- **Videoscopy**
- **Ultrasound**

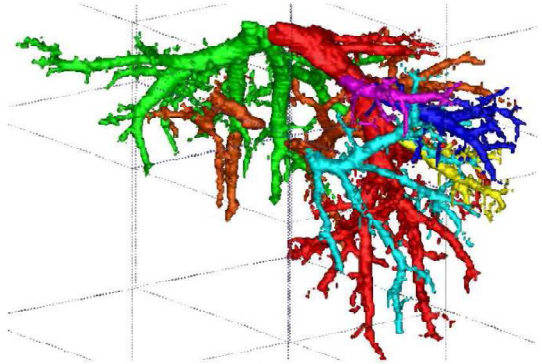

(a)

i) Orientation of the external view

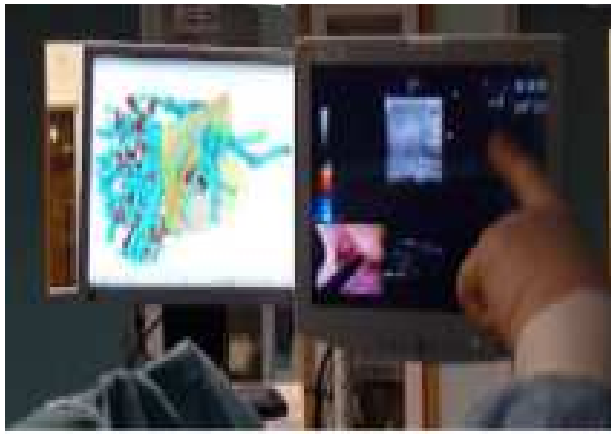

ii) Finding correspondences to the US

Oslo University Hospital

Brain tumor resection
- 3D ultrasound
- neuronavigation

SonoWand

Intraoperative angiography

- **Mobile C-arm**

- **Fixed angiographic equipment**

Fixed C-arm system in operating room

- **High image quality**
- **Rotational angiography - 3 D**

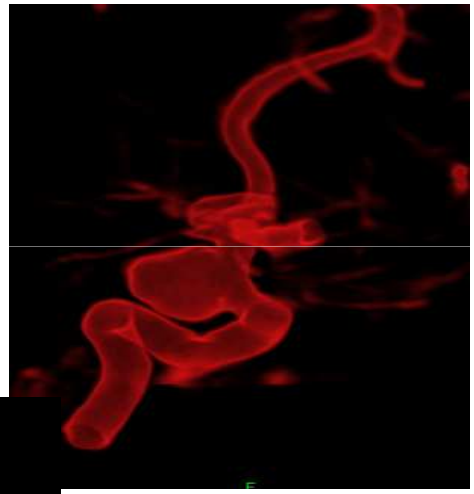

- **CT- like images**

The multipurpose hybrid angiography operating room

- **Multiaxis**

- **Increased flexibility**
- **Coverage**
- **Parking position**
- **Integrated navigation**

The multipurpose hybrid angio suite - net OR area 70 m²

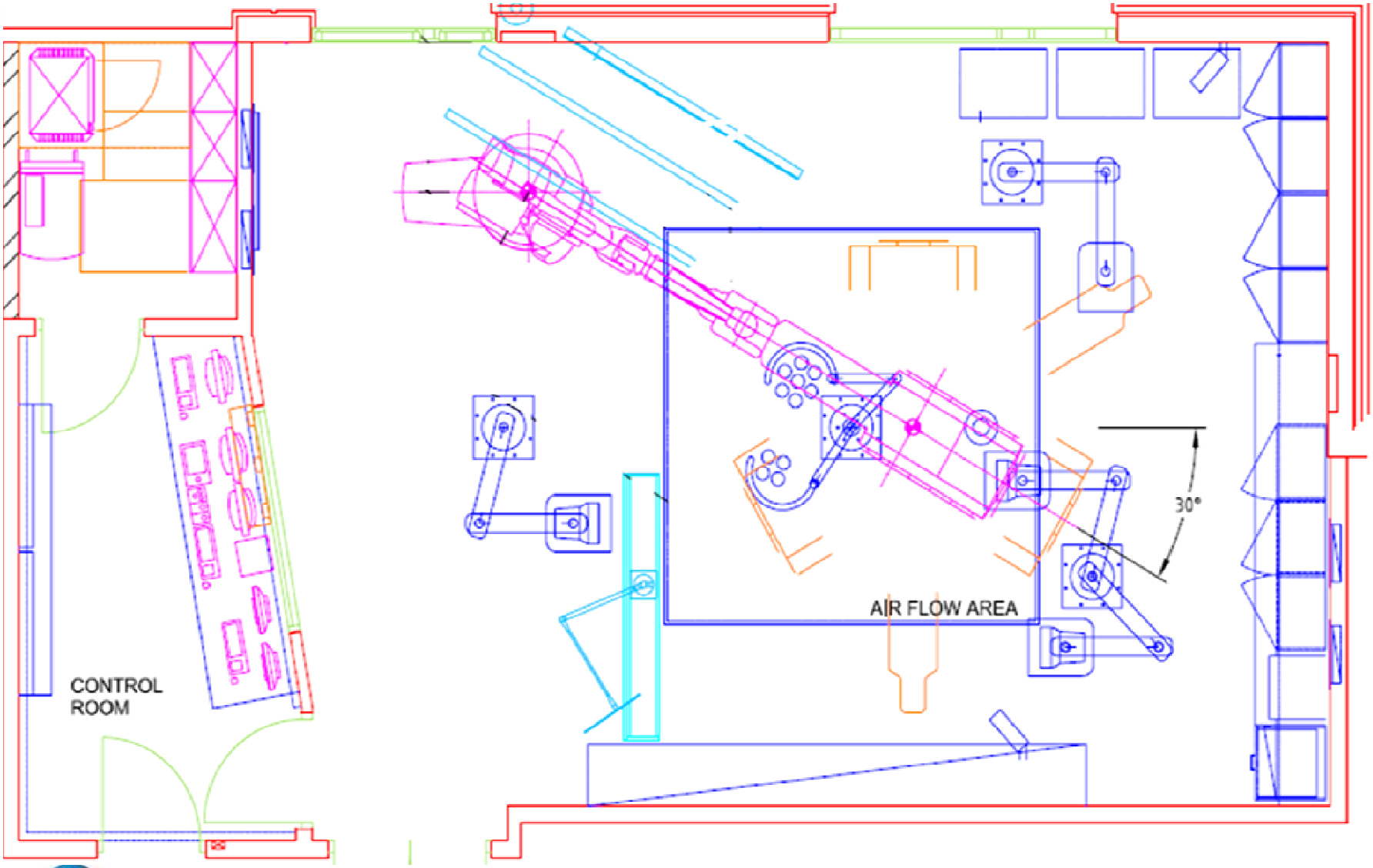

Coronary artery surgery

Intraoperative angiography detects 4% graft failure in coronary artery bypass surgery

PK Hol. Ann Thorac Surg 2004;78:502-8

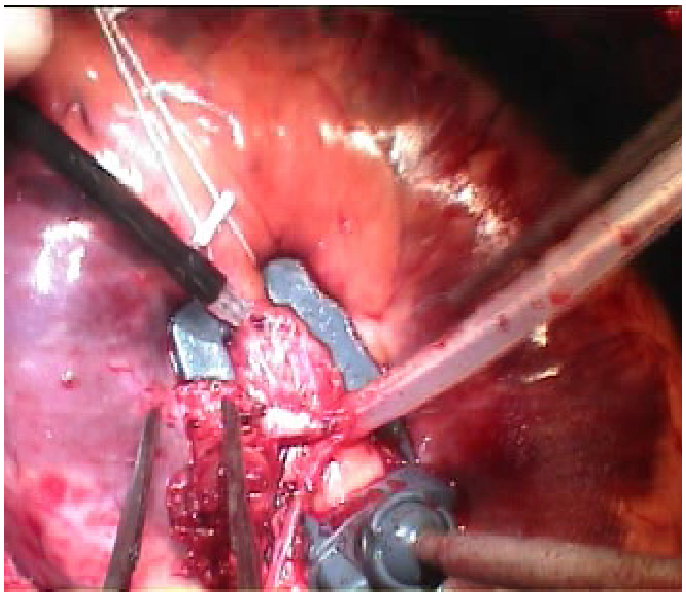

Transapical valve implantation (TAVI)

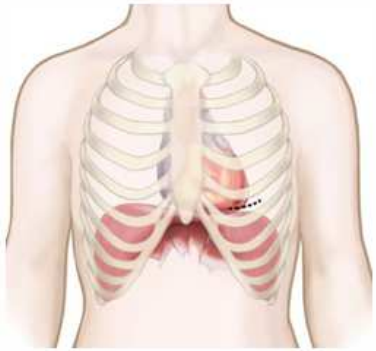

Direct Access to the apex

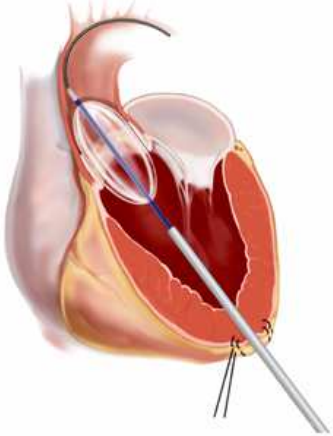

Balloon valvuloplasty

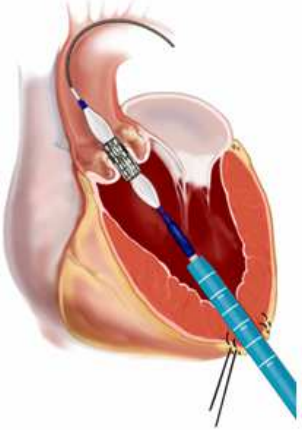

Native valve crossing

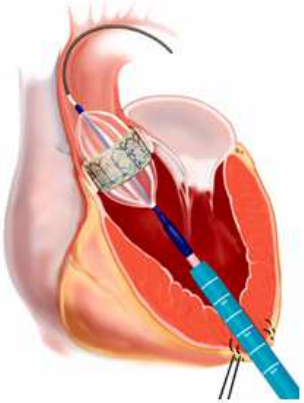

Edwards SAPIEN™ THV deployment

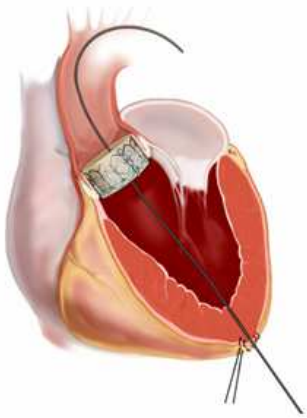

Final assesment

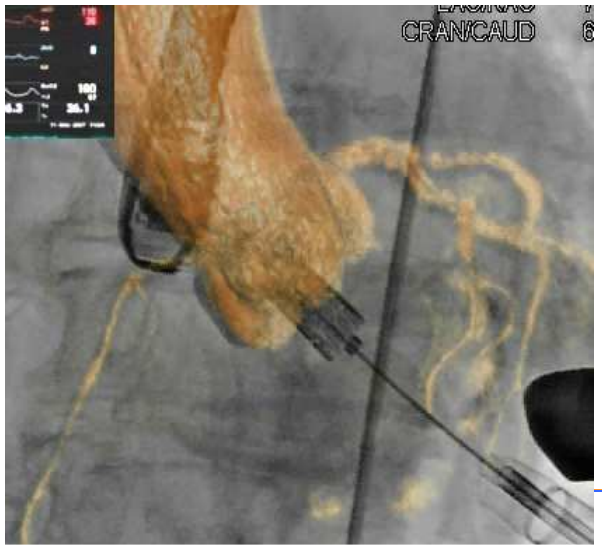

Neurosurgery - Neuroradiology

Aneurysme

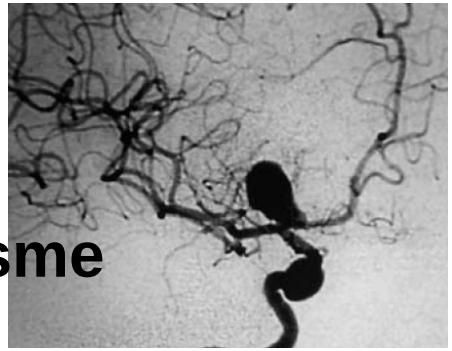

AVM

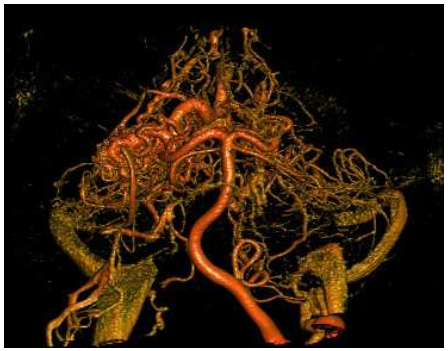

Spinal

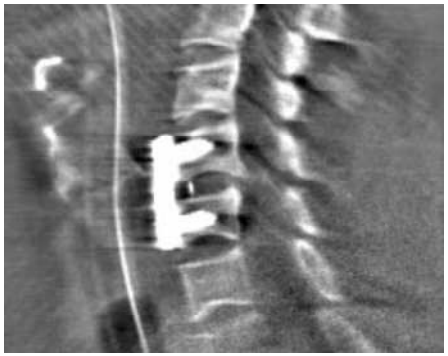

Cochlear Implant

Intraoperative Flat Detector Computed Tomography of temporal bones demonstrates correct position of Cochlear Implant (CI) electrode

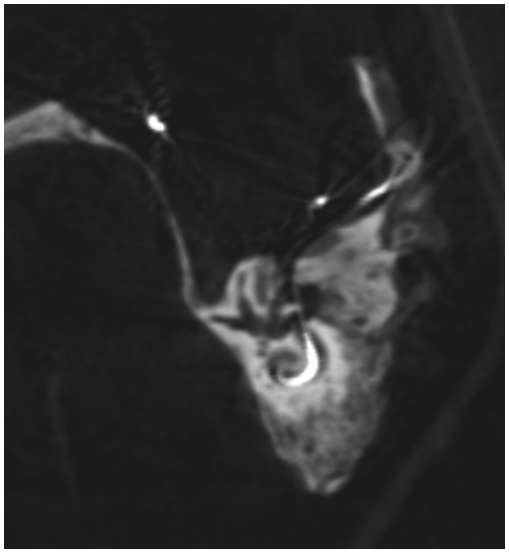

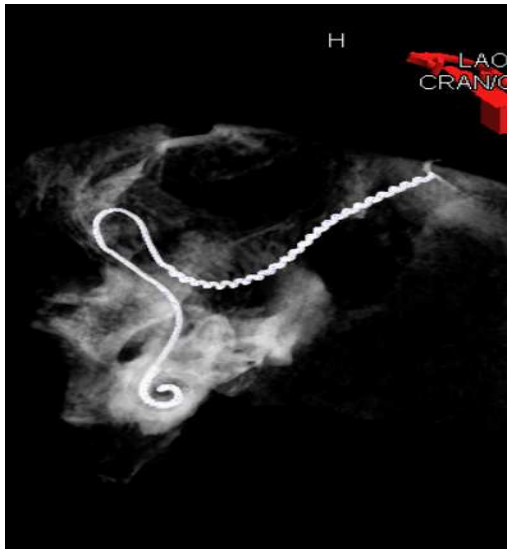

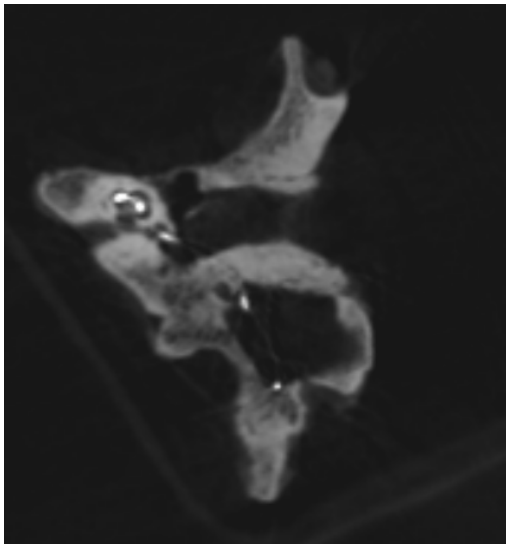

Intraoperative angiography

- **Quality assessment tool**
- **Guidance of surgical prosedure**
- **Combined interventional prosedyre and surgery**
- **High risk interventional prosedures**

Intraoperative angiography /hybrid angio OR suits

- **Great potential**
- **Increased used**

Intraoperative MR

Ultra low field

Biplanar magnet design

Low to mid field



Mid field

GE Open

0.5 T

Vertical gap

High field 1.5 T Movable

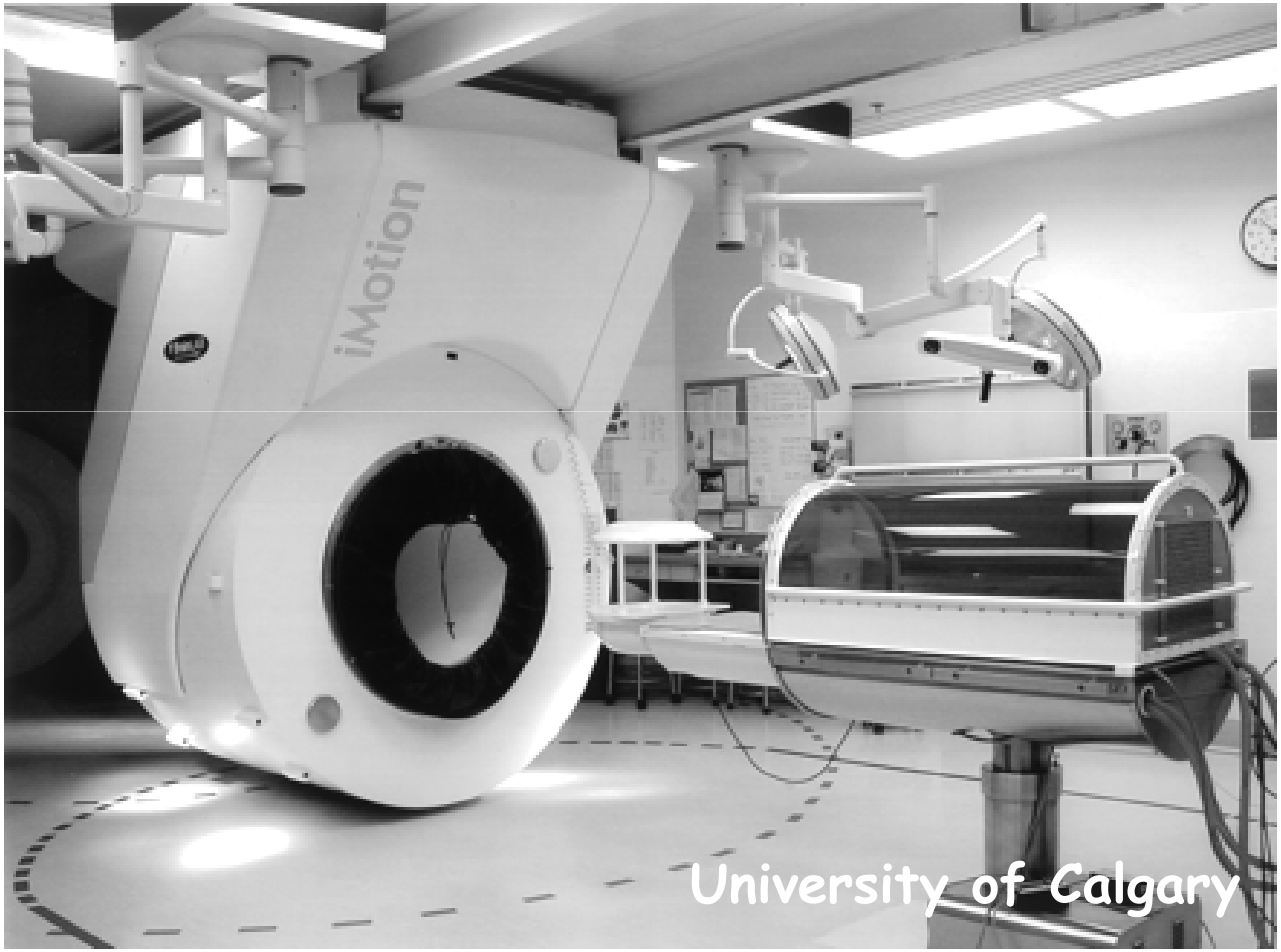

High field Closed bore MR in OR

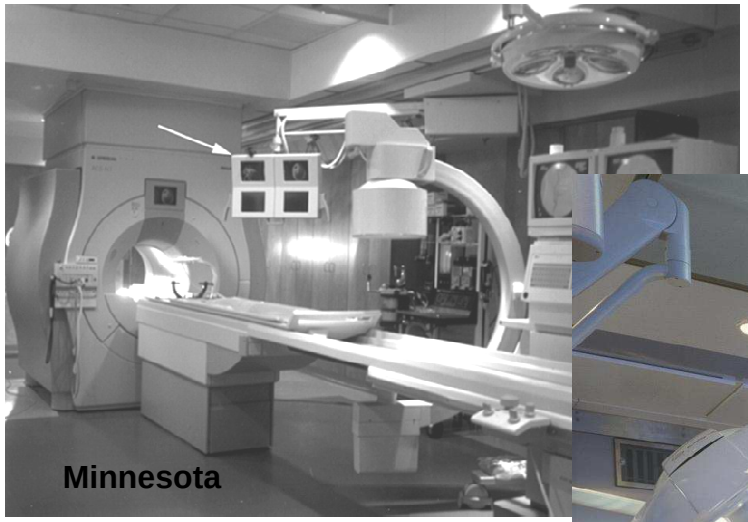

Oslo University Hospital

Dual room MR suite

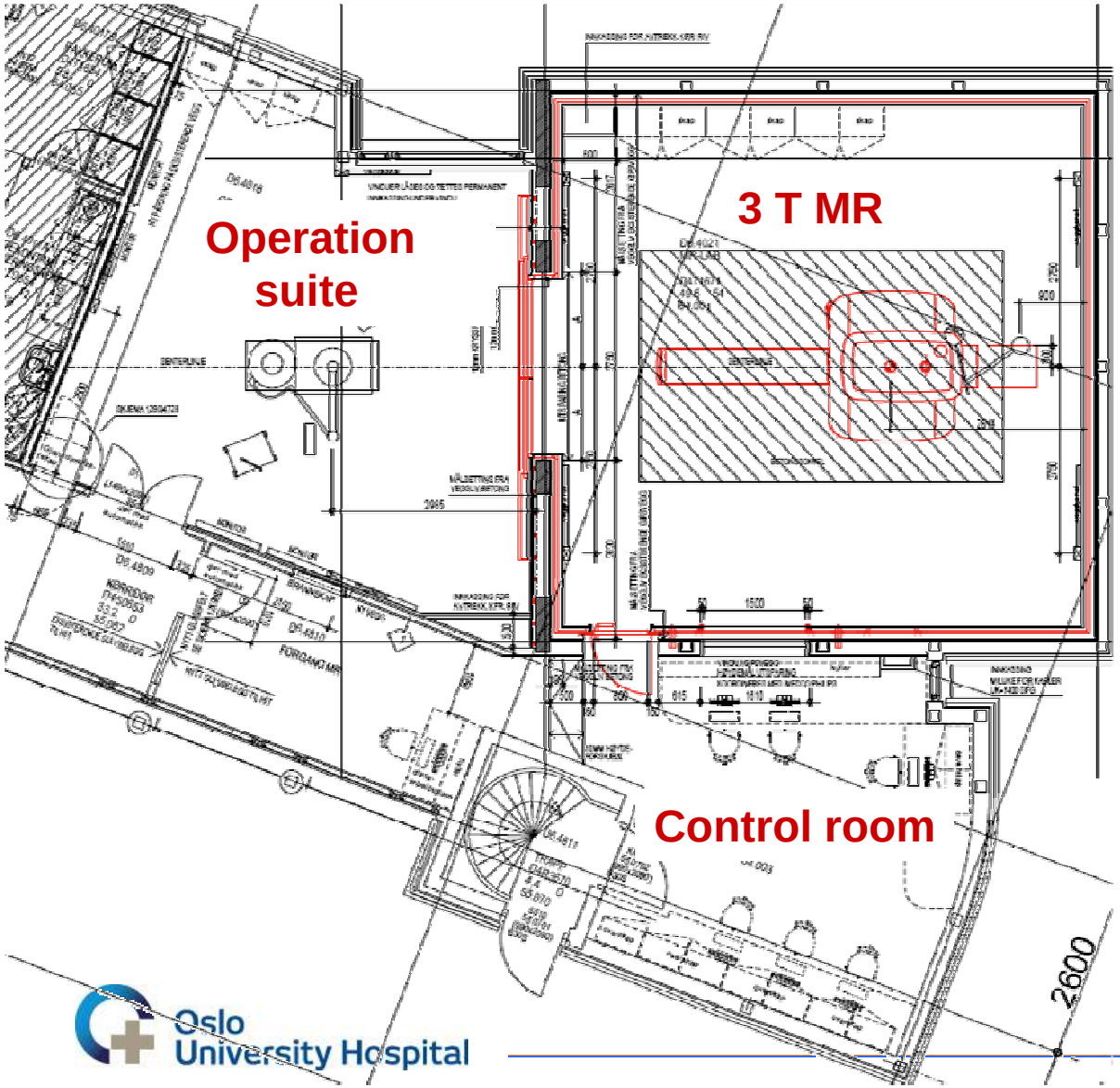

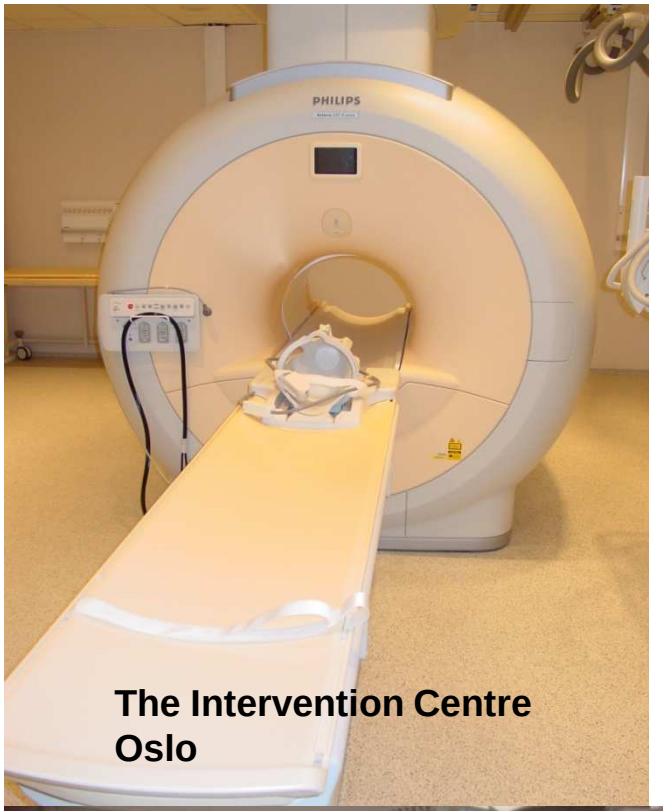

The Intervention Centre Oslo

Interface transfer board

Fixed (headclamp) positioning in and out between OR-table and scanner

Tokai, Japan

St Luc, Brussels

Single & Multiple OR Layout

Single OR
Brigham and Women's Hosp, Boston

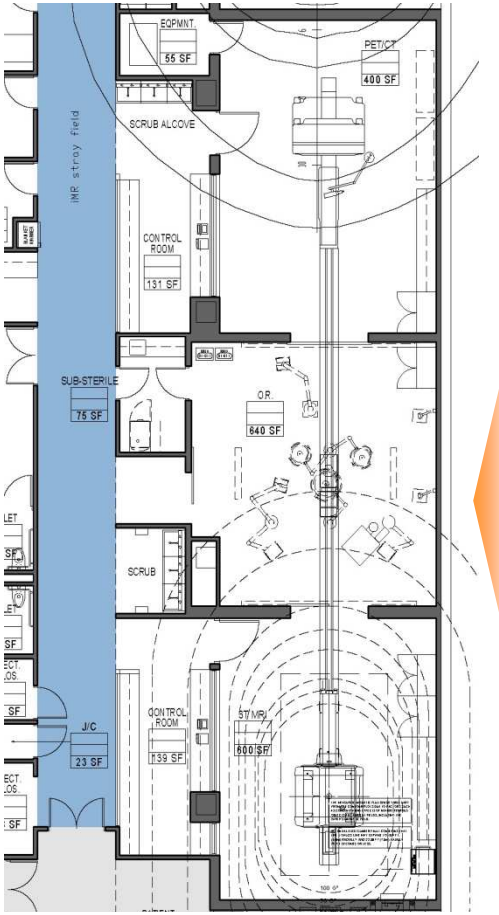

Multiple OR
Barrow Neurological Institute, Phoenix

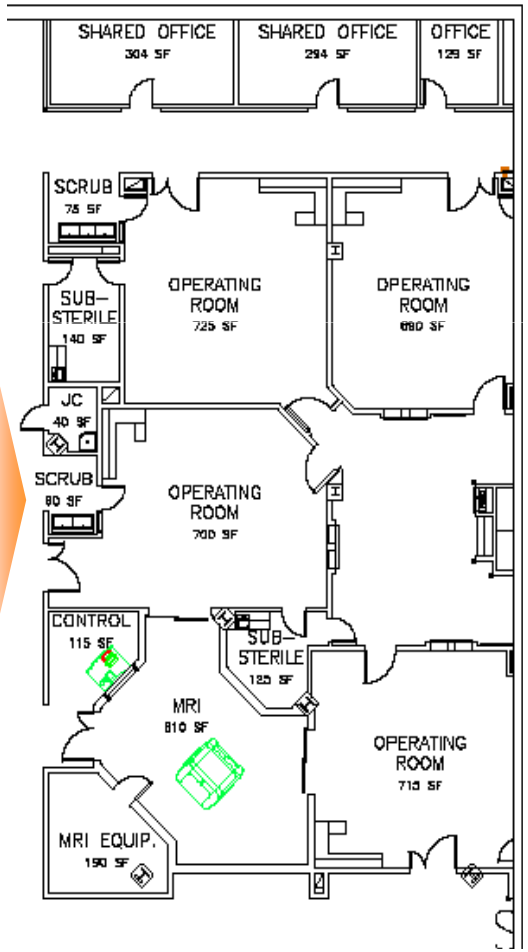

Oslo University Hospital

Biplanar magnets

Needle placements / biopsies

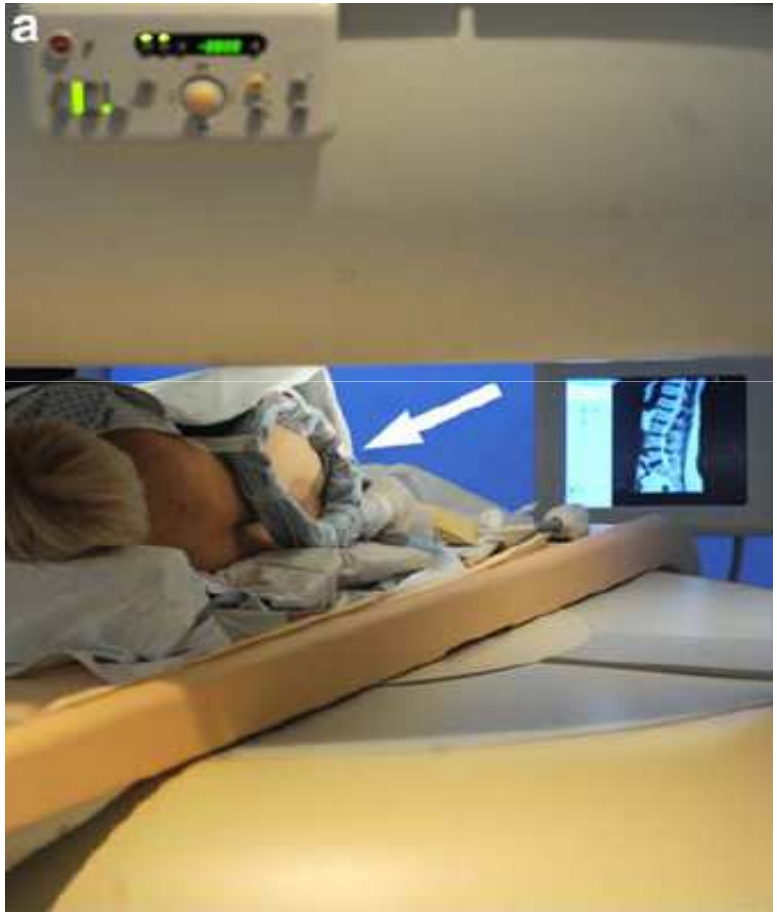

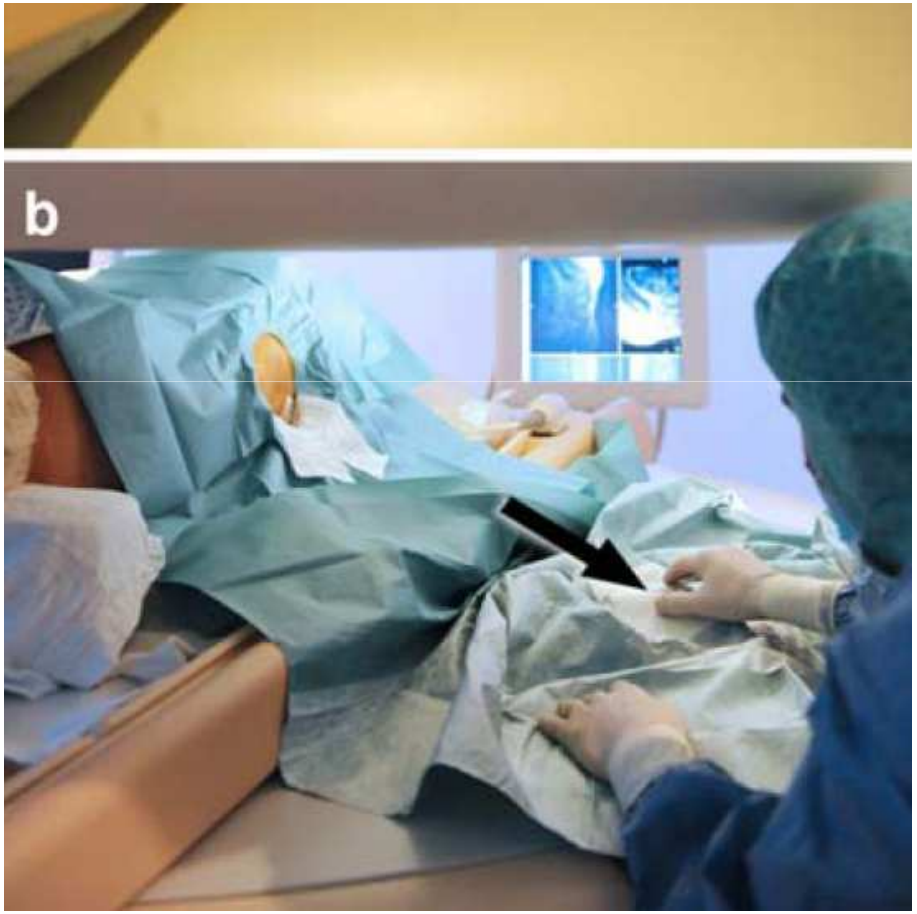

Charité, Berlin

MR GE Open

Direct guidance of tumor resection
Interactive scanplane tracking

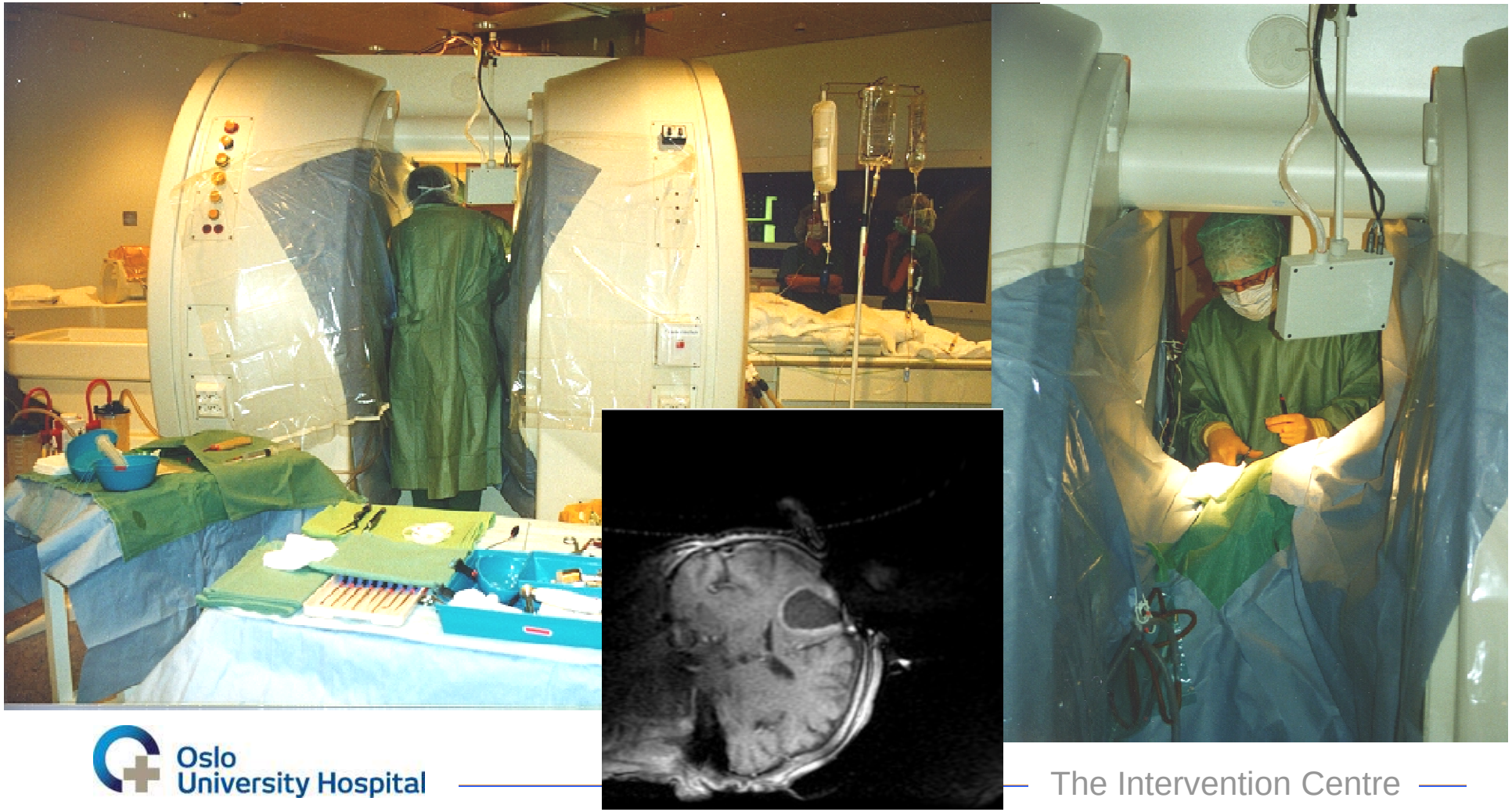

Closed bore scanner:

Brain biopsy (and brain tumor resection) in head end of MR scanner

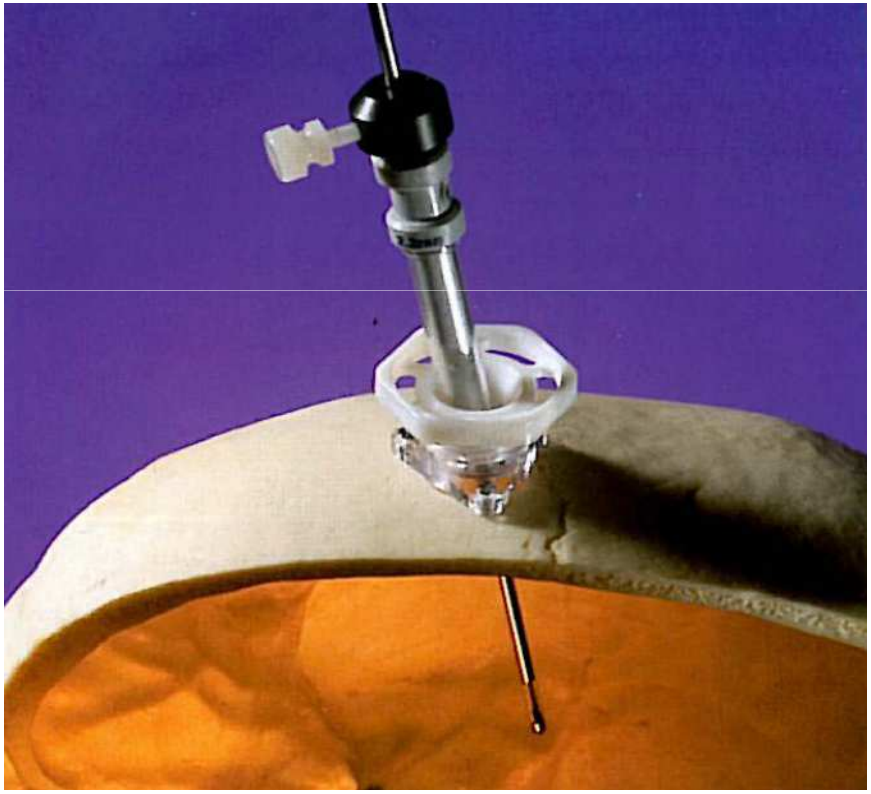

University of Minnesota

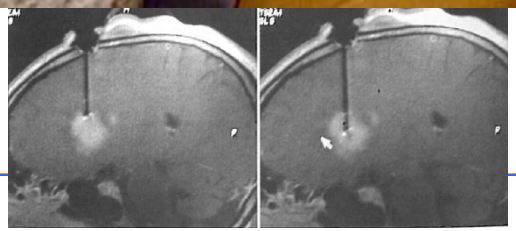

Oslo University Hospital

Closed bore scanner:

Surgery outside the 5 Gauss line

Standard instruments/equipment

Patient transfer

Navigation system

Robotic surgery

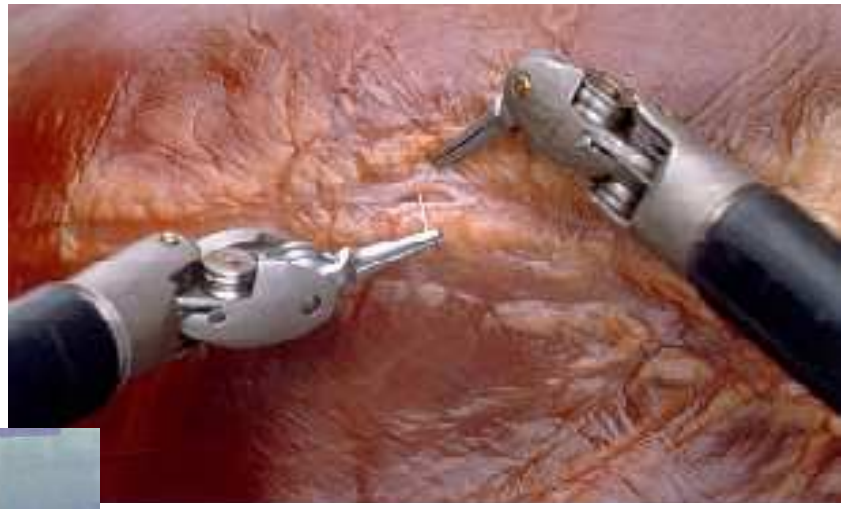

- Telemanipulators
- Lack of haptic feedback
- Almost no autimatically performed robotic tasks

MR compatible robots

Minityrized robots



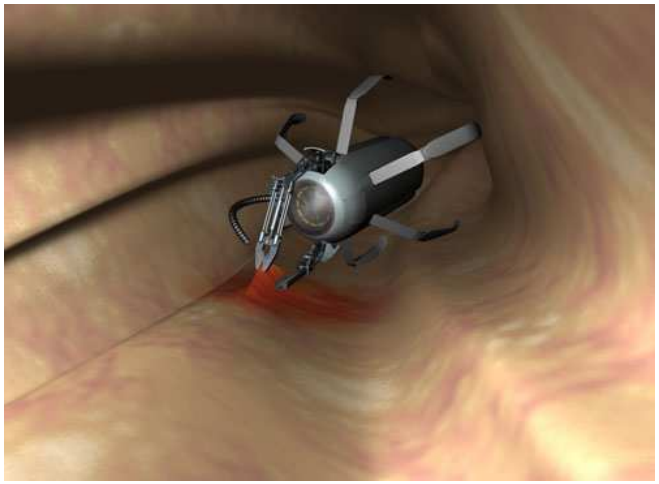

Cultural challenges

In industry:

When new technology is introduced, the structure is adjusted to the new methods

In hospitals:

When new technology is introduced, the technology has to adjust to the existing structure

Organizational consequences

Technology demands a flexible hospital structure

Organ clinics
Cross-disciplinary technology centres

Organization

Organized in existing department:

- **Surgery**
- **Radiology**

Organized in new cross-disiplinary department:

- **Resource for all departments**
- **Technology staff**
- **Updated equipment**

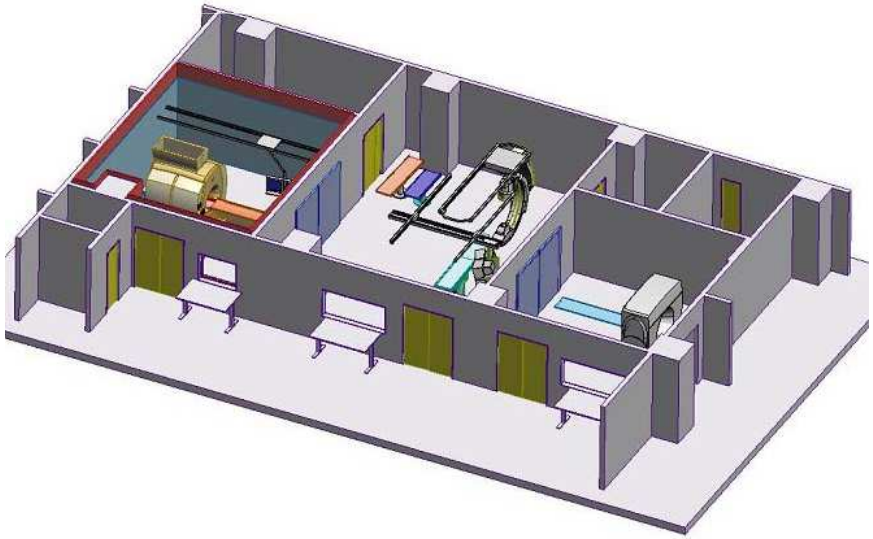

It is not the strongest, nor the most intelligent who survive, but those most responsive to change

Charles Darwin (1809-1888)